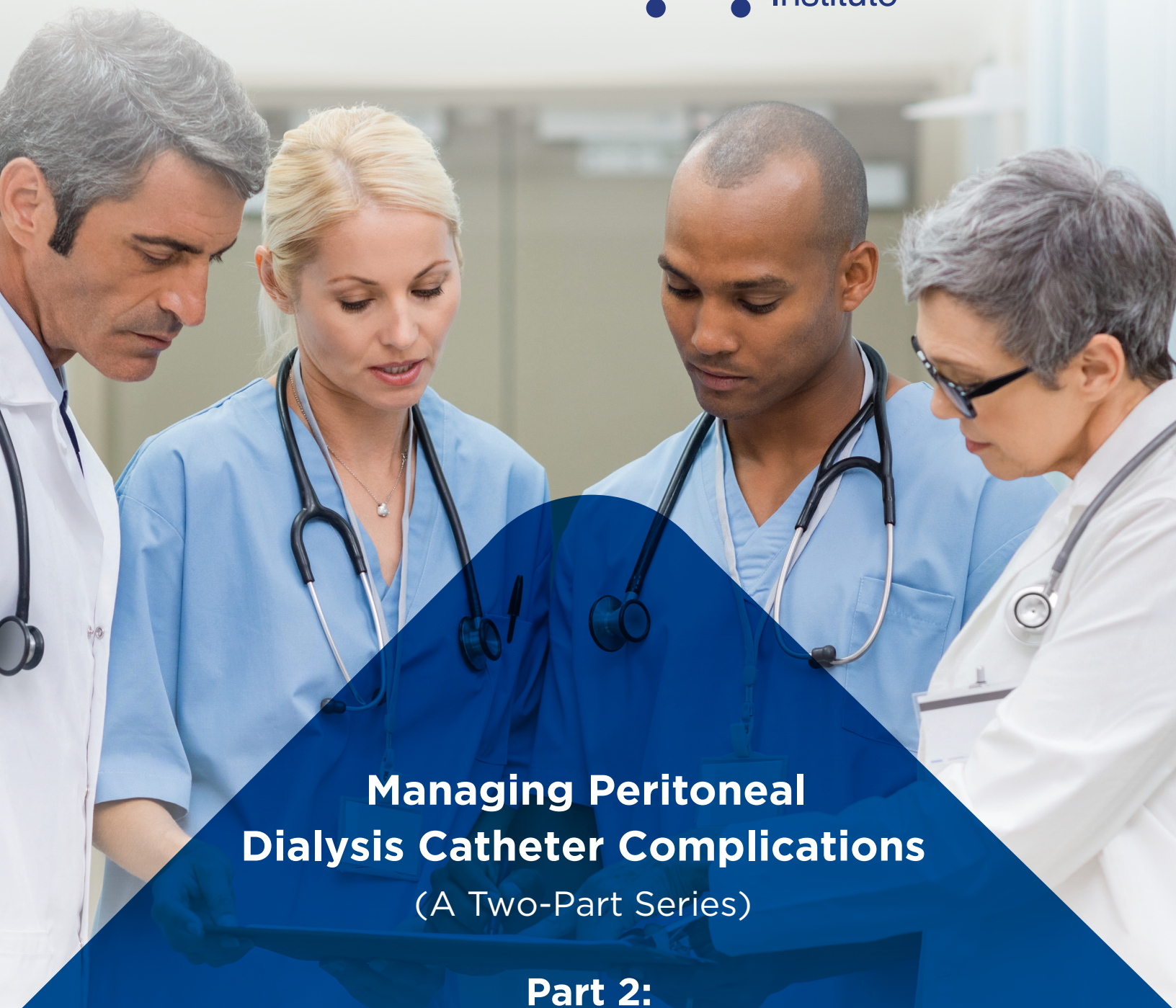

Managing Peritoneal Dialysis Catheter Complications

(A Two-Part Series)

Part 2: Exit-Site/Tunnel Infections, Relapsing Peritonitis, and Acute Abdominal Emergencies

John H. Crabtree, MD
Visiting Clinical Faculty, Division of Nephrology and Hypertension
Harbor-University of California Los Angeles Medical Center
Torrance, California

**Managing PD Catheter
Complications**

**Part 2: Exit-Site/Tunnel Infections,
Relapsing Peritonitis, and Acute
Abdominal Emergencies**

Course Outline

- **Exit-site and Tunnel Infections**
- **Surgical Management**
- **Simultaneous Catheter Replacement for Relapsing Peritonitis**
- **Acute Abdominal Emergencies**

**Managing Peritoneal Dialysis Catheter
Complications**

**Part 2: Exit-Site/Tunnel Infections, Relapsing
Peritonitis, and Acute Abdominal Emergencies**

John H. Crabtree, MD
Visiting Clinical Faculty, Division of Nephrology and Hypertension
Harbor-University of California Los Angeles Medical Center
Torrance, California

Baxter



HomeTherapies
Institute

For informational purposes only. Health care providers should exercise their own judgment in determining whether any particular procedure or treatment is appropriate for their patients.

© 2018 Baxter International Inc. All rights reserved.

**Managing PD Catheter Complications
Part 2: Exit-Site/Tunnel Infections,
Relapsing Peritonitis, and Acute
Abdominal Emergencies**

Objectives

- 01** Evaluate the catheter exit-site/subcutaneous tunnel and diagnose infection
- 02** Discuss surgical management and treatment options for exit-site and tunnel infections
- 03** Detail the indications for simultaneous catheter replacement for relapsing peritonitis
- 04** List acute abdominal emergencies that may be initially mistaken for dialysis-related peritonitis
- 05** Review Case Studies



My Notes:

Slide 4

Infectious complications are the most common reason for loss of the peritoneal dialysis catheter and transfer of the patient to hemodialysis.

In this presentation, our objectives will be to:


- Evaluate the catheter exit-site/subcutaneous tunnel and diagnose infection
- Discuss surgical management and treatment options for exit-site and tunnel infections
- Detail the indications for simultaneous catheter replacement for relapsing peritonitis
- List acute abdominal emergencies that may be initially mistaken for dialysis-related peritonitis
- Review case studies

**Managing PD Catheter Complications
Part 2: Exit-Site/Tunnel Infections,
Relapsing Peritonitis, and Acute
Abdominal Emergencies**

Course Outline

- **Exit-site and tunnel infections**
- **Surgical management**
- **Simultaneous catheter replacement for relapsing peritonitis**
- **Acute abdominal emergencies**

My Notes:



EXIT-SITE AND TUNNEL INFECTIONS

Evaluate the catheter exit-site/subcutaneous tunnel and diagnose infection

**Managing PD Catheter Complications
Part 2: Exit-Site/Tunnel Infections,
Relapsing Peritonitis, and Acute
Abdominal Emergencies**

Exit-site classification terminology

- **Crust:** pale or dark yellow hardened drainage (serum with white blood cells) may be combined with cuticle.
- **Cuticle:** overgrowth of cornified epidermis around the sinus rim of the exit-site. In combination with exudate, a crust is formed.
- **Epithelium:** epidermal cell layer lining the sinus
- **Erythema:** red or bright pink color. Light pale pink or purplish discoloration is not considered erythema.
- **Exit-site:** point where the PD catheter exits the body which includes the most external part of the sinus track and surrounding skin.
- **External exit:** visible exit-site (outside of the sinus rim) which can be seen without lifting the catheter.
- **Granulation tissue:** flat, firm, dull, typically not moist, usually no vessels visible.
- **Proud flesh:** bulging granulation tissue, shiny, moist, numerous vessels visible, fragile, bleeds easily, frequently covered with scab or crust.
- **Scab:** hardened serum and blood (evidence of bleeding).
- **Slightly exuberant granulation tissue:** slightly protruding, delicate, some vessels visible, frequently covered by difficult to detach scab or crust.
- **Tunnel:** path created by catheter under the skin between the exit-site and the peritoneal cavity. Located between the superficial and deep cuffs.
- **Visible sinus:** outermost part of the sinus track (inside the sinus rim) which is visible after lifting the catheter or moving it laterally.

Modified from Twardowski ZJ, Prowant BF. Classification of normal and diseased exit-sites. Perit Dial Int 1996; 16 (Suppl 3): S32-50.



My Notes:

Slide 6

Evaluation and classification of catheter exit-sites requires that we be familiar with a few terms to facilitate communication, standardize clinical documentation, and appropriately direct diagnosis and treatment.¹

**Managing PD Catheter Complications
Part 2: Exit-Site/Tunnel Infections,
Relapsing Peritonitis, and Acute
Abdominal Emergencies**

Exit-site classification system

Sign/Symptom	Perfect	Good	Equivocal	Acute Infection	Chronic Infection	Traumatized
Pain/Tenderness	None	None	None	Pain, tenderness	Pain, tenderness may be present	Depends on severity of trauma
Color	Natural	Natural or pale pink < 13 mm	Bright pink < 13 mm	Bright pink or red ≥ 13 mm	Natural or pale pink < 13 mm	Depends on severity of injury
Scab	None	None	None	Around or within sinus	Around or within sinus	Present
Crust	None	Small or specks of crust on dressing	Present.	Around or within sinus	Around or within sinus	May be present
Drainage						
External	None	None	None. Dried exudate on dressing	Purulent or bloody	Purulent or bloody	Bloody. May be purulent after 48 hrs.
Sinus	Dry or exudate barely visible	Dry or exudate barely visible	Purulent or bloody serous	Purulent or bloody	Purulent or bloody	Bloody. May be purulent after 48 hrs.
Granulation Tissue						
External	None	None	Plain or slightly exuberant	Exuberant	Exuberant	Plain or slightly exuberant
Sinus	None	Flat firm dull beyond epithelium	Slightly exuberant	Exuberant	Exuberant	Plain or slightly exuberant
Swelling	None	None	None	Swelling present	May be present	May be present
Epithelium	Covers whole visible sinus	Partly covering sinus	Absent or covers part of sinus	Absent or covers part of sinus	Absent or covers part of sinus	May recede

Modified from Twardowski ZJ, Prowant BF. Classification of normal and diseased exit-sites. Perit Dial Int 1996; 16 (Suppl 3): S32-50.



My Notes:

Slide 7

Using these terms, a classification systems was developed by Twardowski and Prowant that provided a detailed assessment of the catheter exit site.¹

A chart displaying this classification system is an invaluable reference in every PD clinic. You may review this Classification System in our off-line materials.


**Managing PD Catheter Complications
Part 2: Exit-Site/Tunnel Infections,
Relapsing Peritonitis, and Acute
Abdominal Emergencies**

Exit-site scoring system *

Clinical Feature	0 Point	1 Point	2 Points
Swelling	No	exit-site only; < 5 mm	> 5 mm and/or tunnel
Crust	No	< 5 mm	> 5 mm
Redness	No	< 5 mm	> 5 mm
Pain	No	Slight	Severe
Drainage	No	Serous	Purulent
Granulation tissue	No	Slightly exuberant	Exuberant

Infection should be assumed with exit-site score ≥ 4 .
Purulent drainage or exuberant granulation tissue, even if alone, is sufficient to indicate infection.
A score of less than 4 may or may not represent infection.

* Modified from:
• Schaefer et al. Intermittent versus continuous intraperitoneal glycopeptide/ceftazidime treatment in children with peritoneal dialysis-associated peritonitis. J Am Soc Nephrol 1999; 10:136-45.
• Elamin et al. Low sensitivity of the exit-site scoring system in detecting exit-site infections in peritoneal dialysis patients. Clin Nephrol 2014; 81:100-4.



My Notes:

Slide 8

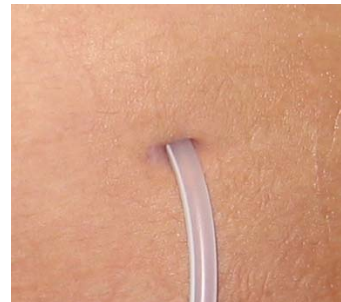A simplified system to assist in specifically identifying an exit site infection is shown here based upon scoring the presence and degree of swelling, crust, redness, pain, drainage, and granulation tissue.^{2,3}

Infection should be assumed with an exit-site score of 4 or greater; although, purulent drainage or exuberant granulation tissue (proud flesh), even if alone, is sufficient to indicate infection.³

**Managing PD Catheter Complications
Part 2: Exit-Site/Tunnel Infections,
Relapsing Peritonitis, and Acute
Abdominal Emergencies**

Exit-site classification

- DESCRIBE THE CLINICAL FEATURES OF THIS EXIT-SITE.
- HOW WOULD YOU CLASSIFY THIS EXIT-SITE?



My Notes:

Slide 9

Based upon what we have been said about exit site assessment parameters, how would you describe the clinical features of this exit-site?

How would you classify this exit-site?

**Managing PD Catheter Complications
Part 2: Exit-Site/Tunnel Infections,
Relapsing Peritonitis, and Acute
Abdominal Emergencies**

Normal exit-site

- Natural skin color.
- No scab, crust, cuticle, or granulation tissue
- No visible drainage
- Epithelium covers whole visible sinus
- Epithelium is snug around the catheter




My Notes:

Slide 10

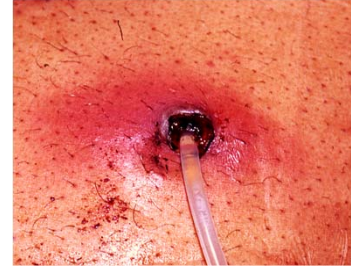This exit site would be best assessed as normal or, using the terms of Twardowski and Prowant, a perfect exit-site:¹

- Natural skin color.
- No scab, crust, cuticle, or granulation tissue
- No visible drainage
- Epithelium covers whole visible sinus
- Epithelium is snug around the catheter

**Managing PD Catheter Complications
Part 2: Exit-Site/Tunnel Infections,
Relapsing Peritonitis, and Acute
Abdominal Emergencies**

Exit-site infection

- DESCRIBE THE CLINICAL FEATURES OF THIS EXIT-SITE.
- HOW WOULD YOU CLASSIFY THIS EXIT-SITE?



My Notes:

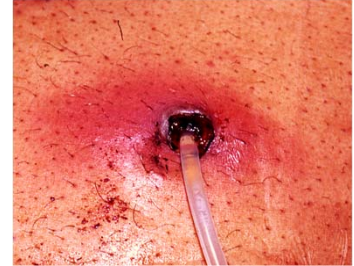Slide 11

Describe the clinical features and how you would classify it.

**Managing PD Catheter Complications
Part 2: Exit-Site/Tunnel Infections,
Relapsing Peritonitis, and Acute
Abdominal Emergencies**

Acute exit-site infection

- Erythema \geq 13 mm
- Swelling of skin around exit-site
- Epithelium absent within the sinus
- Early cuticle formation
- Bloody discharge on skin and within sinus
- Exuberant granulation tissue



My Notes:

Slide 12

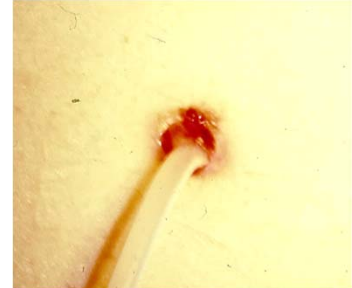It is an acute exit-site infection:¹

- Erythema \geq 13 mm.
- Swelling of skin around exit-site
- Epithelium absent within the sinus
- Early cuticle formation
- Bloody discharge on skin and within sinus
- Exuberant granulation tissue

**Managing PD Catheter Complications
Part 2: Exit-Site/Tunnel Infections,
Relapsing Peritonitis, and Acute
Abdominal Emergencies**

Exit-site infection

- DESCRIBE THE CLINICAL FEATURES OF THIS EXIT-SITE.
- HOW WOULD YOU CLASSIFY THIS EXIT-SITE?



My Notes:

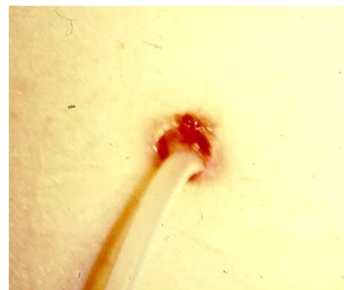Slide 13

Describe its features and how you would classify it.

**Managing PD Catheter Complications
Part 2: Exit-Site/Tunnel Infections,
Relapsing Peritonitis, and Acute
Abdominal Emergencies**

Chronic exit-site infection

- Pale pink skin at sinus rim < 13 mm
- No swelling
- Epithelium absent in sinus
- Purulent discharge within sinus
- Exuberant granulation tissue
- Minimal presence of cuticle



My Notes:

Slide 14

Chronic exit-site infection:¹

- Pale pink skin at sinus rim < 13 mm
- No swelling
- Epithelium absent in sinus
- Purulent discharge within sinus
- Exuberant granulation tissue
- Minimal presence of cuticle

**Managing PD Catheter Complications
Part 2: Exit-Site/Tunnel Infections,
Relapsing Peritonitis, and Acute
Abdominal Emergencies**

Assessment of exit-site infection

Historical Factors

- Noncompliance with exit-site care protocol
- Episode of contamination
- Trauma to exit-site
- Insufficient therapy or noncompliance to treatment of previous exit-site infection episode
- Poor glycemic control
- Known *Staphylococcus aureus* nasal carriage



My Notes:

Slide 15

Historical Factors include:^{4,5,6}

- Noncompliance with exit-site care protocol including handwashing, cleansing, prophylaxis, dressings, and catheter immobilization
- Episode of contamination, e.g. immersion in contaminated water, urinary or fecal incontinence, exposure to animal dander/hair or other environmental contaminants
- Trauma to exit-site, e.g., pulling or excessive tension on catheter, irritation from belts, clothing or seat belts, forcible removing of scabs or crust during exit-site care
- Insufficient therapy or noncompliance to treatment of previous exit-site infection episode
- Poor glycemic control in diabetic patients
- Known *Staphylococcus aureus* nasal carriage

**Managing PD Catheter Complications
Part 2: Exit-Site/Tunnel Infections,
Relapsing Peritonitis, and Acute
Abdominal Emergencies**

Assessment of exit-site infection

Physical Exam

- Location of exit-site
- Pathologic dermatologic conditions in vicinity of exit-site
- Appropriateness of exit-site protection
- Manner of catheter immobilization



My Notes:

Slide 16

Physical Exam:^{5,6}

- Location of exit-site relative to visibility, belt line, skin creases and folds, proximity to stomas, feeding tubes, suprapubic catheters, or other devices
- Pathologic dermatologic conditions in vicinity of exit-site, e.g. psoriasis, intertrigo, infected inclusion cysts or similar inflammatory skin lesions
- Appropriateness of exit-site protection, e.g., integrity of dressings, if used
- Manner of catheter immobilization

**Managing PD Catheter Complications
Part 2: Exit-Site/Tunnel Infections,
Relapsing Peritonitis, and Acute
Abdominal Emergencies**

Initial key activities for exit-site infection



Szeto et al. ISPD catheter-related infection recommendations: 2017 update. Perit Dial Int 2017; 37:141-54.

My Notes:

Slide 17

Initial key activities for exit site infection are:⁶

- Culture and Gram stain of drainage
- Start empiric antibiotic therapy
- Consider ultrasound study of subcutaneous track
- Intensify exit-site care

**Managing PD Catheter Complications
Part 2: Exit-Site/Tunnel Infections,
Relapsing Peritonitis, and Acute
Abdominal Emergencies**

Follow-up key activities for exit-site infection

Antibiotics	Exit-site Care	Glycemic Control	Diagnostic and Labs	Document
-------------	----------------	------------------	---------------------	----------

- Adjust antibiotics to culture and sensitivity results
- Dose and treatment duration according to ISPD guidelines and cultured microorganism
- Review antibiotic/antacid/food interactions with the patient

Szeto et al. ISPD catheter-related infection recommendations: 2017 update. Perit Dial Int 2017; 37:141-54.
Piraino et al. Peritoneal dialysis related infections recommendations: 2005 update. Perit Dial Int 2005; 25:107-31.



My Notes:

Slide 18

Follow-up key activities:^{4,6,7}

- **Antibiotics**
 - Adjust antibiotics to culture and sensitivity results
 - Dose and treatment duration according to ISPD guidelines and cultured microorganism
 - Review antibiotic/antacid/food interactions with the patient
- **Exit-site Care**
 - Review and/or retrain patient in exit-site care protocol
 - Institute hypertonic saline soaks to exit-site 1 to 3 times daily for severe infections
 - Treat exuberant granulation tissue at the exit-site with silver nitrate application
- **Diagnostic and Labs**
 - Perform ultrasound of subcutaneous catheter tunnel and Dacron cuffs towards the end of treatment period or when response to therapy is slow, especially if *Staphylococcus aureus* or *pseudomonas* exit-site infection
 - Culture nose and treat if *Staphylococcus aureus* nasal carrier
 - Repeat culture and Gram stain if treatment response is slow
 - Confirm that diabetic patients have achieved glycemic control
- **Document**
 - Monitor and document condition of exit-site, sinus, and subcutaneous tunnel through close follow-up with patient to evaluate response to treatment plan

**Managing PD Catheter Complications
Part 2: Exit-Site/Tunnel Infections,
Relapsing Peritonitis, and Acute
Abdominal Emergencies**

Key activities for the traumatized exit-site

KEY ACTIVITIES:

- Culture and Gram stain of purulent exudate and/or drainage if present
- Start broad spectrum systemic antibiotics prophylactically for at least a week
- Adjust antibiotics to culture results if done
- Continue antibiotics until 7 days after achieving a good appearance
- Gentle handling and immobilization of the catheter

Khanna R, Twardowski ZJ. Recommendations for treatment of exit-site pathology. Perit Dial Int 1996; 16:S100-4.



My Notes:

Slide 19

Key activities for the traumatized exit-site include:⁸

- Culture and Gram stain of purulent exudate and/or drainage if present
- Start broad spectrum systemic antibiotics prophylactically for at least a week
- Adjust antibiotics to culture results if done
- Continue antibiotics until 7 days after achieving a good appearance
- Gentle handling and immobilization of the catheter

**Managing PD Catheter Complications
Part 2: Exit-Site/Tunnel Infections,
Relapsing Peritonitis, and Acute
Abdominal Emergencies**

Patient education for exit-site trauma

PATIENT EDUCATION:

- Avoid pulling or excessive tension of the catheter
- Anchor catheter in natural position
- Avoid irritation from belts, clothing, or seat belts
- Avoid scratching or picking at exit-sites
- Do not forcibly remove scabs or crusts
- Do not sleep on abdomen



My Notes:


Slide 20

Patient education for exit-site infection should include the following:⁴

- Avoid pulling or excessive tension of the catheter
- Anchor catheter in natural position
- Avoid irritation from belts, clothing, or seat belts
- Avoid scratching or picking at exit-sites
- Do not forcibly remove scabs or crusts
- Do not sleep on abdomen

**Managing PD Catheter Complications
Part 2: Exit-Site/Tunnel Infections,
Relapsing Peritonitis, and Acute
Abdominal Emergencies**

Key assessments for tunnel infection



Clinical


- Pain and tenderness over subcutaneous track of the catheter
- Swelling, induration, and redness over track
- Signs of exit-site infection may or may not be present

Diagnostic

- Palpation over track or gentle pull of catheter may produce purulent discharge from exit sinus
- If clinical signs are equivocal, ultrasound imaging performed to assess for fluid around catheter and cuffs

SWELLING AND ERYTHEMA OVER SUBCUTANEOUS TRACK OF CATHETER

Szeto et al. ISPD catheter-related infection recommendations: 2017 update. Perit Dial Int 2017; 37:141-54.



My Notes:

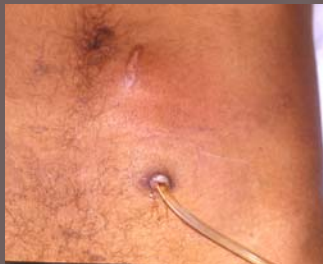Slide 21

In the case of tunnel infection, key clinical findings include:^{4,6}

- Pain and tenderness over subcutaneous track of the catheter
- Swelling, induration, and redness over track
- Signs of exit-site infection may or may not be present
- Palpation over track or gentle pull of catheter may produce purulent discharge from exit sinus
- If clinical signs are equivocal, ultrasound imaging performed to assess for fluid around catheter and cuffs

**Managing PD Catheter Complications
Part 2: Exit-Site/Tunnel Infections,
Relapsing Peritonitis, and Acute
Abdominal Emergencies**

Key activities for tunnel infection



INITIAL ACTIVITIES:

- Culture and Gram stain
- Initiate empiric antibiotics
- Refer to surgeon to determine intervention

SURGICAL THERAPEUTICS:

- Surgical intervention may include:
 - Unroofing/cuff shaving
 - Simultaneous catheter replacement
 - Catheter splicing
- Infected wounds are left open to heal by secondary intention

SWELLING AND ERYTHEMA OVER SUBCUTANEOUS TRACK OF CATHETER AND SIGNS OF CHRONIC EXIT-SITE INFECTION.

My Notes:

Slide 22

Initial Activities:^{4,9}

- Culture and Gram stain of purulent exudate and/or drainage if present
- Initiate empiric antibiotics that includes *Staphylococcus aureus* coverage. If history of pseudomonas exit-site infection, empiric antibiotics should cover this organism
- Refer to surgeon to determine intervention

Surgical Therapeutics:

- Surgical intervention may include:
 - Unroofing of catheter tunnel with shaving of cuff
 - Simultaneous catheter removal and insertion of new catheter at new site
 - Catheter splicing to new exit-site location with removal of infected segment of catheter along with superficial cuff
- Infected wounds are left open and require local care until healed by secondary intention

**Managing PD Catheter Complications
Part 2: Exit-Site/Tunnel Infections,
Relapsing Peritonitis, and Acute
Abdominal Emergencies**

Course Outline

- **Exit-site and tunnel infections**
- **Surgical management**
- **Simultaneous catheter replacement for relapsing peritonitis**
- **Acute abdominal emergencies**

My Notes:

02

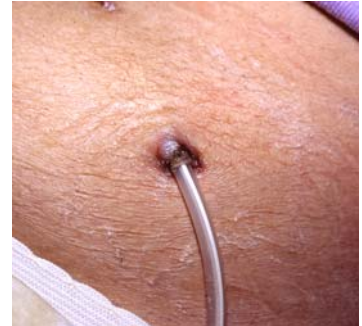SURGICAL MANAGEMENT

Discuss surgical management and treatment options for exit-site and tunnel infections

**Managing PD Catheter Complications
Part 2: Exit-Site/Tunnel Infections,
Relapsing Peritonitis, and Acute
Abdominal Emergencies**

Superficial cuff extrusion

- What causes superficial cuff extrusion?
- How should this cuff extrusion be managed?



My Notes:

Slide 24

Superficial cuff extrusion.

- What causes superficial cuff extrusion?
- How should this cuff extrusion be managed?

**Managing PD Catheter Complications
Part 2: Exit-Site/Tunnel Infections,
Relapsing Peritonitis, and Acute
Abdominal Emergencies**

Superficial cuff extrusion

Causes of superficial cuff extrusion:

- Excessively bent straight intercuff tubing segment
- Cuff positioned too close to the exit-site

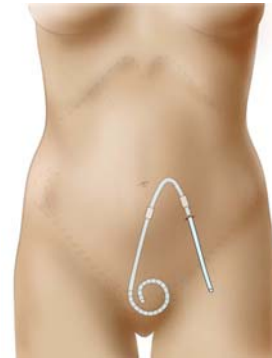

Illustration courtesy of John Crabtree, MD



My Notes:

Slide 25

Causes of superficial cuff extrusion:⁴

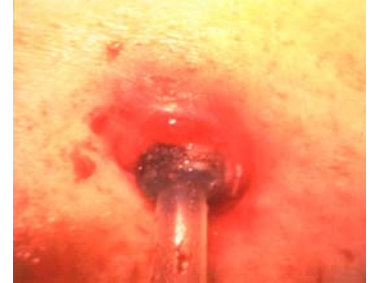- If a catheter with a straight intercuff tubing segment is bent excessively to produce a downwardly directed exit-site, shape-memory resiliency forces are created that lead to straightening of the catheter over time causing the superficial cuff to move toward and extrude through the exit-site.
- If the cuff was positioned too close to the exit-site at the time of catheter placement, the risk for extrusion is increased.

**Managing PD Catheter Complications
Part 2: Exit-Site/Tunnel Infections,
Relapsing Peritonitis, and Acute
Abdominal Emergencies**

Why should the extruding superficial cuff be managed?

Consequences of superficial cuff extrusion:

- If the extruding cuff is not managed, it soon becomes seeded with bacteria and predisposes to exit-site infection.
- A cuff that has completely extruded still remains a source of bacteria in the vicinity of the exit-site.
- During routine exit-site care, unavoidable wetting of an extruded bacterial-laden cuff leads to constant exit-site contamination.



Debowski et al. Cuff extrusion in peritoneal dialysis: single-centre experience with cuff-shaving procedure in five patients over a 4-year period. Clin Kidney J. 2017; 10:131-4.

My Notes:

Slide 26

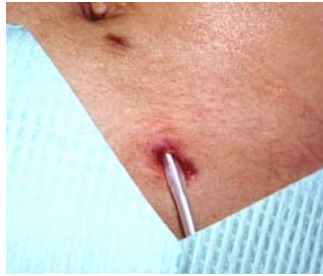What is the concern about an extruded cuff and how should it be managed?

Consequences of cuff extrusion:^{4,10}

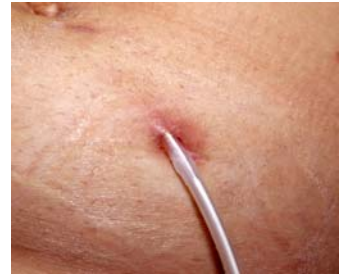- If the extruding cuff is not managed, it soon becomes seeded with bacteria and predisposes to exit-site infection.
- A cuff that has completely extruded still remains a source of bacteria in the vicinity of the exit-site.
- During routine exit-site care, unavoidable wetting of an extruded bacterial-laden cuff leads to constant exit-site contamination.

**Managing PD Catheter Complications
Part 2: Exit-Site/Tunnel Infections,
Relapsing Peritonitis, and Acute
Abdominal Emergencies**

Shaving of extruding superficial cuff



If not completely extruded, the cuff is gently delivered through the sinus and shaved off of the catheter tubing with a scalpel.



Appearance of the healing exit-site 2 weeks following shaving of the superficial cuff



My Notes:

Slide 27

To avoid the complications, the superficial cuff should be removed.⁴

- If not completely extruded, the cuff is gently delivered through the exit sinus and shaved off of the catheter tubing with a scalpel.
- Removal of an extruding cuff will allow the exit-site to promptly heal.

**Managing PD Catheter Complications
Part 2: Exit-Site/Tunnel Infections,
Relapsing Peritonitis, and Acute
Abdominal Emergencies**

**Surgical salvage from chronic exit-site infection:
unroofing/cuff shaving**

- If not treated, infection will eventually extend to peritoneum and result in loss of catheter
- Unroofing the subcutaneous tunnel track and shaving of the superficial cuff can achieve long-term salvage of catheter
- Peritoneal dialysis is not interrupted
- Unroofing/cuff shaving not indicated if deep cuff is involved or if there is concurrent peritonitis



My Notes:

Slide 28

Chronic exit-site infections can be salvaged by unroofing of the subcutaneous catheter track and shaving of the infected superficial cuff.¹¹

- If not treated, infection will eventually extend to peritoneum and result in loss of catheter
- Unroofing the subcutaneous tunnel track and shaving of the superficial cuff can achieve long-term salvage of catheter
- Peritoneal dialysis is not interrupted
- Unroofing/cuff shaving not indicated if deep cuff is involved or if there is concurrent peritonitis

**Managing PD Catheter Complications
Part 2: Exit-Site/Tunnel Infections,
Relapsing Peritonitis, and Acute
Abdominal Emergencies**

Unroofing/cuff shaving procedure

Incision removes skin of exit-site and unroofs track to cuff.

Cuff mobilized and infected tissues are excised.

Shave cuff with #15 blade. Change blade frequently.

Repetitive slices are used to remove all cuff material.

Crabtree JH, Burchette RJ. Surgical salvage of peritoneal dialysis catheters from chronic exit-site and tunnel infections. Am J Surg 2005; 190:4-8

My Notes:

Slide 29

The procedure of unroofing the tunnel track and shaving of the superficial cuff is as follows:¹¹

- An incision is made to encompass the skin of the exit-site and extends over the subcutaneous route of the catheter until the superficial cuff is encountered.
- The cuff is mobilized by dividing the fibrous sheath around the catheter just deep to the cuff. This will allow the catheter cuff to be delivered to the surface of the wound. The exit-site skin and granulation tissue of the track are completely excised. Inspection is performed to make sure that the infectious process has not progressed to the deep cuff.
- The cuff is carefully shaved with repetitive slices of a #15 blade. Change the blade frequently so that you are always cutting with a sharp edge. You may accidentally cut into the lumen of the catheter if you are pushing down too hard with a dull blade.

**Managing PD Catheter Complications
Part 2: Exit-Site/Tunnel Infections,
Relapsing Peritonitis, and Acute
Abdominal Emergencies**

Unroofing/cuff shaving procedure

Direct catheter out medial end of wound and secure.			Wound packed open and allowed to heal by secondary intention.
6-Weeks postoperative unroofing/cuff shaving.			1-Year postoperative unroofing/cuff shaving.

Crabtree JH, Burchette RJ. Surgical salvage of peritoneal dialysis catheters from chronic exit-site and tunnel infections. Am J Surg 2005; 190:4-8

My Notes:

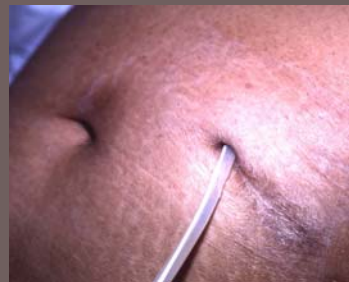Slide 30

- Direct the catheter out the medial end of the wound and immobilize it with benzoin and adhesive strips. The hemostat in the photo indicates the shaved superficial cuff.¹¹
- The wound is packed open with a saline wet-to-dry dressing and allowed to heal secondarily. If there was no abscess or cellulitis, the lateral portion of the wound may be partially closed.
- Most wounds are healed with 4-8 weeks.⁹
- Long-term, the patient will develop a mature healthy exit-site.¹¹

**Managing PD Catheter Complications
Part 2: Exit-Site/Tunnel Infections,
Relapsing Peritonitis, and Acute
Abdominal Emergencies**

Unroofing and cuff shaving

- The unroofing and cuff shaving procedure is capable of producing a long-term stable exit-site in selected cases
- However, the procedure may not improve a poorly located exit-site that initiated the exit-site infection



PERFECT EXIT-SITE FOLLOWING UNROOFING/CUFF SHAVING.



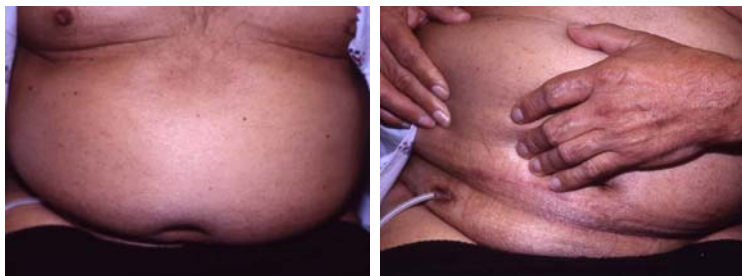My Notes:

Slide 31

- The unroofing and cuff shaving procedure is capable of producing a long-term stable exit-site in selected cases¹¹
- However, the procedure may not improve a poorly located exit-site that initiated the exit-site infection⁹

**Managing PD Catheter Complications
Part 2: Exit-Site/Tunnel Infections,
Relapsing Peritonitis, and Acute
Abdominal Emergencies**

Chronic infection due to poor exit-site location



Unroofing and cuff shaving will not improve this exit-site location

My Notes:

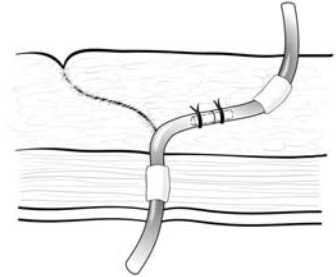
Slide 32

- Chronic infections may be due to poor exit-site location. This patient had multiple exit-site infections during his first year of peritoneal dialysis. His catheter had excellent flow function.
- Unroofing and cuff shaving will not improve this exit-site location.
- How can this situation be salvaged?

**Managing PD Catheter Complications
Part 2: Exit-Site/Tunnel Infections,
Relapsing Peritonitis, and Acute
Abdominal Emergencies**

Surgical salvage by catheter splicing

- Ideal when poor exit-site location is contributing factor to chronic infection
- Peritoneal dialysis is not interrupted
- Catheter splicing not indicated if infection encountered in deep tunnel track, deep cuff involved, or concurrent peritonitis



Crabtree JH. Rescue and salvage procedures for mechanical and infectious complications of peritoneal dialysis. Int J Artif Organs 2006; 29:57-64



My Notes:

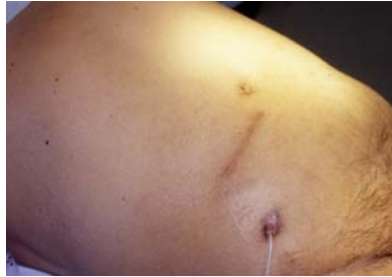Slide 33

One option is to relocate the exit-site of the dialysis catheter to a more environmentally friendly area using a splicing technique.

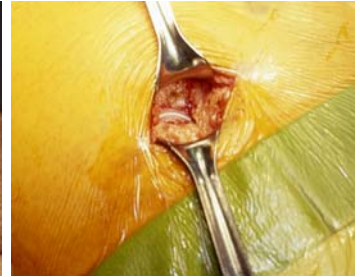- This is an ideal technique when poor exit-site location is a contributing factor to chronic infection, especially if the catheter has good flow function. In addition, this technique would be appropriate for broken catheters that are too short for external repair.⁹
- The main advantage is that peritoneal dialysis therapy is not interrupted.⁹
- Catheter splicing is not indicated if infection is encountered in the deep tunnel track, if the deep cuff is involved, or if the patient has concurrent peritonitis.¹²

**Managing PD Catheter Complications
Part 2: Exit-Site/Tunnel Infections,
Relapsing Peritonitis, and Acute
Abdominal Emergencies**

Surgical salvage by catheter splicing



Catheter exit-site will be relocated to upper abdomen above pannus.



Exit-site shielded from the surgical field. Catheter intercepted just above fascia.



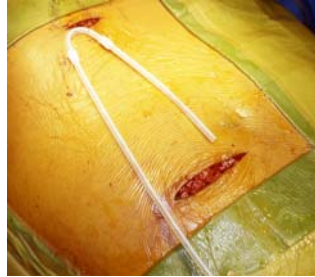My Notes:

Slide 34

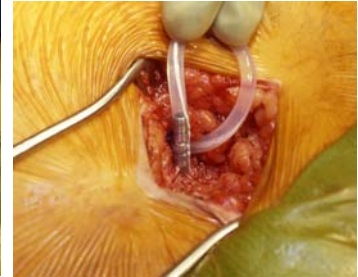- This photo sequence demonstrates the catheter splicing technique to relocate the exit-site to the upper abdomen in the patient previously shown.
- The patient's head will always be toward the left in the photos. Note that when the patient is recumbent, there is no clue to the skin fold created by his pendulous abdomen. This stresses the importance of preoperative evaluation where the patient is examined in both the sitting and recumbent positions.
- The entire abdomen is prepped and draped; however, the old exit-site is excluded with toweling and further secured by application of an iodine impregnated plastic adhesive barrier to prevent cross contamination.
- The previous paramedian incision is entered and the catheter is intercepted as it enters the fascia. Examine for evidence of infection extending to the intercuff catheter segment. If purulent fluid or granulation tissue is present, the procedure should be abandoned and the catheter removed.⁹ No signs of infection were noted in this particular case.

**Managing PD Catheter Complications
Part 2: Exit-Site/Tunnel Infections,
Relapsing Peritonitis, and Acute
Abdominal Emergencies**

Surgical salvage by catheter splicing



Splice segment cut to length and tunneled from upper to lower incision.



Catheter cut 2.5-cm above level of fascia and joined to splice segment with titanium connector.



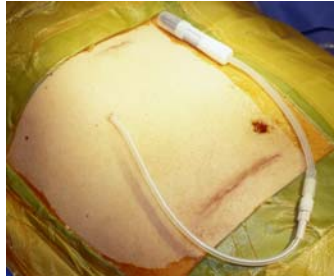
My Notes:

Slide 35

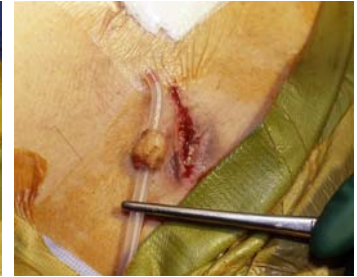- Depending on the length needed, the spliced segment can be prepared from another PD catheter. The catheter is tunneled between the upper and lower incisions.
- The native catheter is cut 2.5 cm above the level of the fascia and joined to the splice segment with a titanium connector. Sutures tied over the respective connector grooves further secures the 2 catheter ends.⁹

**Managing PD Catheter Complications
Part 2: Exit-Site/Tunnel Infections,
Relapsing Peritonitis, and Acute
Abdominal Emergencies**

Surgical salvage by catheter splicing



Catheter tunneled to designated new exit-site. Wounds are closed and dressed.



After wounds are covered, the remainder of catheter is removed through old exit-site.

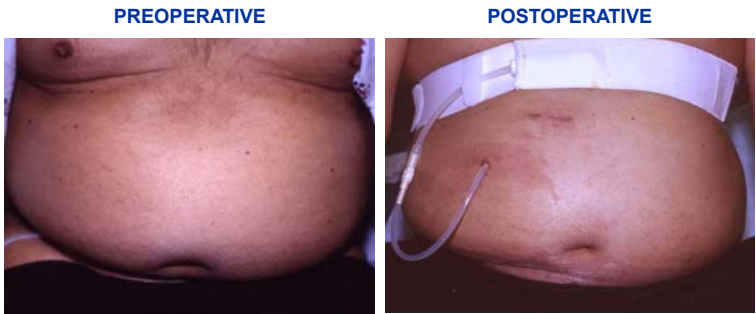
My Notes:

Slide 36

- The catheter is tunneled to the designated new exit-site. The wounds are closed and dressings applied.
- After the wounds are covered, the remainder of the old catheter is removed through the old exit-site. The wound is left open and dressed wet-to-dry.⁹

**Managing PD Catheter Complications
Part 2: Exit-Site/Tunnel Infections,
Relapsing Peritonitis, and Acute
Abdominal Emergencies**

Surgical salvage by catheter splicing



Performed without interruption of peritoneal dialysis.



My Notes:

Slide 37

- These are the before and after photos.
- The attractive features of this technique are that it can be performed under local anesthesia and peritoneal dialysis is not interrupted.

**Managing PD Catheter Complications
Part 2: Exit-Site/Tunnel Infections,
Relapsing Peritonitis, and Acute
Abdominal Emergencies**

Course Outline

- **Exit-site and tunnel infections**
- **Surgical management**
- **Simultaneous catheter replacement for relapsing peritonitis**
- **Acute abdominal emergencies**

My Notes:



**SIMULTANEOUS CATHETER REPLACEMENT
FOR RELAPSING PERITONITIS**

Detail the indications for simultaneous catheter replacement for relapsing peritonitis

**Managing PD Catheter Complications
Part 2: Exit-Site/Tunnel Infections,
Relapsing Peritonitis, and Acute
Abdominal Emergencies**

Relapsing peritonitis

Key assessments

- Relapsing peritonitis is an episode that occurs within 4 weeks of completion of therapy of a prior episode with the same organism or one sterile episode
- Catheter should be removed when relapsing peritonitis is recognized, usually evident by the first or second relapse
- Alternatively, simultaneous catheter replacement may be considered if:
 - Peritonitis not due to mycobacteria, fungi, enteric organisms or pseudomonas species
 - Clinical signs of peritonitis must be resolved and peritoneal leukocyte count is < 100/μL

Crabtree JH, Siddiqui RA. Simultaneous catheter replacement for infectious and mechanical complications without interruption of peritoneal dialysis. Perit Dial Int 2016; 36:182-7.

Mitra A, Tellebaum I. Is it safe to simultaneously remove and replace infected peritoneal dialysis catheters? Review of the literature and suggested guidelines. Adv Perit Dial 2003; 255-9.



My Notes:


Slide 39

- Relapsing peritonitis is an episode that occurs within 4 weeks of completion of therapy of a prior episode with the same organism or one sterile episode¹³
- Catheter should be removed when relapsing peritonitis is recognized, usually evident by the first or second relapse⁹
- Alternatively, simultaneous catheter replacement may be considered if:^{13,14}
 - Peritonitis not due to mycobacteria, fungi, enteric organisms or pseudomonas species
 - Clinical signs of peritonitis must be resolved and peritoneal leukocyte count is <100/μL

**Managing PD Catheter Complications
Part 2: Exit-Site/Tunnel Infections,
Relapsing Peritonitis, and Acute
Abdominal Emergencies**

Key Activities for simultaneous catheter replacement for relapsing peritonitis without interruption of PD

Diagnostic	Therapeutics
<ul style="list-style-type: none"> Perform abdominal exam to note presence, degree, and location of pain. Assess exit-site and tunnel Consider imaging studies for equivocal abdominal exam to evaluate for possible intra-abdominal abscess Send sample of peritoneal effluent for cell count 	<ul style="list-style-type: none"> Continue appropriate antibiotic coverage for 1 to 2 weeks postoperatively Insert new catheter (clean step) before removal of old catheter (dirty step) Close watertight all penetrating points through musculofascial layers of abdominal wall Utilize intermittent regimen of supine, low-volume PD during interval of postoperative recovery; leave peritoneum dry during ambulatory periods Monitor for signs of infection or leak



My Notes:

Slide 40

There are key diagnostic and therapeutic activities involved with simultaneous catheter replacement for relapsing peritonitis without interruption of PD.

Diagnostic:⁹

- Perform abdominal exam to note presence, degree, and location of pain. Assess exit-site and tunnel
- Consider imaging studies for equivocal abdominal exam to evaluate for possible intra-abdominal abscess
- Send sample of peritoneal effluent for cell count

Therapeutic:^{9,13}

- Continue appropriate antibiotic coverage for 1 to 2 weeks postoperatively
- Insert new catheter (clean step) before removal of old catheter (dirty step)
- Close watertight all penetrating points through musculofascial layers of abdominal wall
- Utilize intermittent regimen of supine, low-volume PD during interval of postoperative recovery; leave peritoneum dry during ambulatory periods
- Monitor for signs of infection or leak


**Managing PD Catheter Complications
Part 2: Exit-Site/Tunnel Infections,
Relapsing Peritonitis, and Acute
Abdominal Emergencies**

Patient education following simultaneous catheter replacement

Patient instructions

- ✓ Provide instruction in dressing care of any open surgical wounds
- ✓ Protect new surgical wounds from cross contamination from infected wounds
- ✓ Advise how to look for signs of infection or leak
- ✓ Review changes in PD technique or modifications in cyclers settings
- ✓ Review antibiotic regimen
- ✓ Schedule retraining for PD technique

Crabtree JH, Siddiqi RA. Simultaneous catheter replacement for infectious and mechanical complications without interruption of peritoneal dialysis. Perit Dial Int 2016; 36:182-7.



My Notes:

Slide 41

Following simultaneous catheter replacement, patient instructions include:¹³

- Provide instruction in dressing care of any open surgical wounds
- Protect new surgical wounds from cross contamination from infected wounds
- Advise how to look for signs of infection or leak
- Review changes in PD technique or modifications in cyclers settings
- Review antibiotic regimen
- Schedule retraining for PD technique

**Managing PD Catheter Complications
Part 2: Exit-Site/Tunnel Infections,
Relapsing Peritonitis, and Acute
Abdominal Emergencies**

Course Outline

- **Exit-site and tunnel infections**
- **Surgical management**
- **Simultaneous catheter replacement for relapsing peritonitis**
- **Acute abdominal emergencies**

My Notes:

04

ACUTE ABDOMINAL EMERGENCIES

Acute abdominal emergencies that may be initially mistaken for dialysis-related peritonitis

**Managing PD Catheter Complications
Part 2: Exit-Site/Tunnel Infections,
Relapsing Peritonitis, and Acute
Abdominal Emergencies**

Acute abdominal emergencies in peritoneal dialysis patients

Most Acute abdominal emergencies that occur in PD patients are the same that occur in the general non-dialysis population

- **Pathological conditions in PD patients include:**
- Acute cholecystitis
- Perforated diverticulitis
- Perforated appendicitis
- Perforated gastroduodenal ulcer
- Ischemic bowel with gangrene
- Iatrogenic bowel perforation (endoscopy)
- Tubo-ovarian abscess
- Perforated intestinal neoplasms
- Bowel perforation by dialysis catheter

Crabtree JH. Rescue and salvage procedures for mechanical and infectious complications of peritoneal dialysis. Int J Artif Organs 2006; 29:67-84



My Notes:

Slide 43

Not infrequently, peritoneal dialysis patients may develop acute abdominal emergencies that require surgical intervention. The dilemma is in differentiating the usual dialysis-related peritonitis from other intra-abdominal pathologies.

The most frequent intra-abdominal pathologies encountered in peritoneal dialysis patients that require surgical intervention are:⁹

- Perforated diverticulitis
- Ischemic bowel with gangrene
- Acute cholecystitis
- Perforated appendicitis
- Iatrogenic bowel perforation (endoscopy)
- Tubo-ovarian abscess
- Bowel perforation by dialysis catheter
- Perforated intestinal neoplasms

**Managing PD Catheter Complications
Part 2: Exit-Site/Tunnel Infections,
Relapsing Peritonitis, and Acute
Abdominal Emergencies**

**Diagnosis of acute abdominal emergencies in
peritoneal dialysis patients is frequently delayed**

Delayed diagnosis is common and mortality rates have been reported to range from 33-57%

- Antibiotic protocol for usual dialysis-related peritonitis may delay diagnosis due to partial treatment
- Several days transpire before culture results return
- Dilutional effects of dialysis may delay localization of pathology
- CT scan less sensitive in peritoneal dialysis patients and negative study may give false sense of security

Crabtree JH. Rescue and salvage procedures for mechanical and infectious complications of peritoneal dialysis. Int J Artif Organs 2006; 29:67-84

My Notes:

Slide 44

Delayed diagnosis and intervention for acute abdominal emergencies are common problems in peritoneal dialysis patients. As a result, there have been reports of mortality rates ranging from 33 to 57%.⁹

There are several reasons that contribute to a delay in diagnosis:

- Antibiotic protocol for usual dialysis-related peritonitis may delay diagnosis due to partial treatment.
- Several days transpire before culture results return.
- Dilution effects of dialysate solution may delay localization of pathology.
- CT scan less sensitive in peritoneal dialysis patients and negative study may give false sense of security.

**Managing PD Catheter Complications
Part 2: Exit-Site/Tunnel Infections,
Relapsing Peritonitis, and Acute
Abdominal Emergencies**

**Assessment of acute abdominal emergencies in
peritoneal dialysis patients**

Suspect intra-abdominal pathology when:

- Culture of multiple enteric organisms or presence of anaerobic pathogens
- Failure to respond appropriately to antibiotic therapy
- Dialysate with fecal material
- Dialysate diarrhea
- Increasing free air in the abdomen

Crabtree JH. Rescue and salvage procedures for mechanical and infectious complications of peritoneal dialysis. Int J Artif Organs 2006; 29:67-84



My Notes:

Slide 45

Suspect intra-abdominal pathology when:⁹

- Cultures show multiple enteric organisms or the presence of anaerobic pathogens
- Failing to respond appropriately to antibiotic therapy
- Certainly the diagnosis is facilitated in those small number of cases where:
 - fecal material is seen in the dialysate
 - the patient is having dialysate diarrhea
 - massive or increasing air in the abdomen

**Managing PD Catheter Complications
Part 2: Exit-Site/Tunnel Infections,
Relapsing Peritonitis, and Acute
Abdominal Emergencies**

**Interventions for acute abdominal emergencies
in peritoneal dialysis patients**

Surgical intervention:

- Consider early exploration when intra-abdominal pathology is suspected. Delays produce high mortality
- Laparoscopy makes it more palatable to offer early surgical exploration
- Perform standard surgical treatment for the diagnosed intra-abdominal pathology
- Remove PD catheter

Crabtree JH. Rescue and salvage procedures for mechanical and infectious complications of peritoneal dialysis. *Int J Artif Organs* 2006; 29:67-84



My Notes:

Slide 46

Surgical Intervention:⁹

- Consider early exploration when intra-abdominal pathology is suspected.
- The availability of laparoscopy allows a lower threshold for early exploration and has less adverse consequences in the event of negative findings.
- Standard surgical treatment should be performed for positive findings.
- The peritoneal dialysis catheter should be removed.

**Managing PD Catheter Complications
Part 2: Exit-Site/Tunnel Infections,
Relapsing Peritonitis, and Acute
Abdominal Emergencies**

Summary

- **Proper assessment** of the PD catheter exit-site is important
- **Familiarity with available interventions** for infectious complications assists in appropriate/timely surgical referrals
- **Early and appropriate interventions** for infectious complications can save PD catheters without interrupting therapy
- **Knowledge of acute Abdominal emergencies** that can initially be mistaken for dialysis-related infections in PD patients is critical



My Notes:

Summary:

- Proper assessment of the PD catheter exit-site is important in determining presence of infection, possible root causes, and designing appropriate therapeutics
- Familiarity with available interventions for infectious complications assists in making appropriate and timely surgical referrals
- Early and appropriate interventions for infectious complications can often save catheters without interruption of PD therapy
- Knowledge of acute Abdominal emergencies that can initially be mistaken for dialysis-related infections is critical in reducing morbidity and mortality of these conditions in PD patients

REFERENCES

1. Twardowski ZJ, Prowant B. "Classification of normal and diseased exit sites." *Perit Dial Int* 16.Suppl 3 (1996): S32-S50.
2. Schaefer F, Klaus G, Muller-Wiefel M, et al. "Intermittent vs continuous intraperitoneal glycopeptide/ceftazidime treatment in children with peritoneal dialysis-associated peritonitis." *J Am Soc Nephrol* 10 (1999): 136-145.
3. Elamin S, Khaier ME, Kaballo BG, Abu-Aisha H. "Low sensitivity of the exit site scoring system in detecting exit site infections in peritoneal dialysis patients." *Clin Nephrol* 81.2 (2014): 100-104.
4. BF, Prowant. "Peritoneal dialysis access." Ponferrada LP, Prowant BF, Satalowich RJ. *Core curriculum for nephrology nursing*. Ed. BF Prowant. 5th. Pitman: American Nephrology Nurses' Association, 2008. 768-795.
5. Crabtree, JH. "Peritoneal dialysis catheter implantation: avoiding problems and optimizing outcomes." *Semin Dial* 28.1 (2015): 12-15.
6. Szeto CC, Li P, Johnson DW, et al. "ISPD catheter-related infection recommendations: 2017 update." *Perit Dial Int* 37 (2017): 141-154.
7. Piraino B, Bailie GR, Bernardini J, et al. "Peritoneal dialysis-related infections recommendations: 2005 update." *Perit Dial Int* 25 (2005): 107-131.
8. Khanna R, Twardowski ZJ. "Recommendations for treatment of exit-site pathology." *Perit Dial Int* 16.Suppl 3 (1996): S51-S70.
9. Crabtree, JH. "Rescue and salvage procedures for mechanical and infectious complications of peritoneal dialysis." *Int J Art Organs* 29.1 (2006): 67-84.
10. Debowski JA, Waerp C, Kjellevold SA, Abedini S. "Cuff extrusion in peritoneal dialysis: single-centre experience with the cuff-shaving procedure in five patients over a 4-year period." *Clin Kidney J* 10.1 (2017): 131-134.
11. Crabtree JH, Burchette RJ. "Surgical salvage of peritoneal dialysis catheters from chronic exit-site and tunnel infections." *Am J Surg* 190 (2005): 4-8.
12. Crabtree JH, Jain A. "Peritoneal dialysis catheters, placement, and care." Daugirdas JT, Blake PG, Ing TS. *Handbook of Dialysis*. Ed. Lippincott Williams & Wilkins. 5th. Philadelphia: Wolters Kluwer Health, 2015. 425-450.
13. Crabtree JH, Siddiqi RA. "Simultaneous catheter replacement for infectious and mechanical complications without interruption of peritoneal dialysis." *Perit Dial Int* 36 (2016): 182-187.

REFERENCES

14. Mitra A, Teitelbaum I. "Is it safe to simultaneously remove and replace infected peritoneal dialysis catheters? Review of the literature and suggested guidelines." *Adv Perit Dial* 19 (2003): 255-259.

Baxter

Baxter Healthcare Corporation
One Baxter Parkway
Deerfield, Illinois 60015 USA

www.baxter.com

Baxter and Home Therapies Institute logo are trademarks of
Baxter International Inc.
Any other trademarks, product brands or images appearing herein
are the property of their respective owners.

USMP/MG232/18-0026d 7/18